



## Renal arcuate vein thrombosis–induced acute kidney injury: a rare multiple-Hit–mediated disease

Clara Pardinhas, Rui Filipe, Paul Vergnaud, Mathilde Grapin, Elsa Ferrière, Anne Jamet, Jacques Fourgeaud, Nicolas da Rocha, Philippe Pérot, Olivia Boyer, et al.

### ► To cite this version:

Clara Pardinhas, Rui Filipe, Paul Vergnaud, Mathilde Grapin, Elsa Ferrière, et al.. Renal arcuate vein thrombosis–induced acute kidney injury: a rare multiple-Hit–mediated disease. *Clinical Kidney Journal*, 2023, 16 (2), pp.367-373. 10.1093/ckj/sfac244 . pasteur-04048752

**HAL Id: pasteur-04048752**

**<https://pasteur.hal.science/pasteur-04048752>**

Submitted on 28 Mar 2023

**HAL** is a multi-disciplinary open access archive for the deposit and dissemination of scientific research documents, whether they are published or not. The documents may come from teaching and research institutions in France or abroad, or from public or private research centers.

L'archive ouverte pluridisciplinaire **HAL**, est destinée au dépôt et à la diffusion de documents scientifiques de niveau recherche, publiés ou non, émanant des établissements d'enseignement et de recherche français ou étrangers, des laboratoires publics ou privés.



Distributed under a Creative Commons Attribution - NonCommercial 4.0 International License

## ORIGINAL ARTICLE

# Renal arcuate vein thrombosis–induced acute kidney injury: a rare multiple-Hit-mediated disease

Clara Pardinhas<sup>1,\*</sup>, Rui Filipe<sup>1,\*</sup>, Paul Vergnaud<sup>2</sup>, Mathilde Grapin<sup>2</sup>, Elsa Ferrière<sup>3</sup>, Anne Jamet<sup>4</sup>, Jacques Fourgeaud<sup>4</sup>, Nicolas Da Rocha<sup>5</sup>, Philippe Pérot<sup>6</sup>, Olivia Boyer<sup>2</sup>, Marion Rabant<sup>1</sup>, Jean-Paul Duong Van Huyen<sup>1,\*</sup> and Pierre Isnard<sup>1,\*</sup>

<sup>1</sup>Department of Pathology, Necker-Enfants Malades Hospital, APHP, Paris, France, <sup>2</sup>Department of Pediatric Nephrology, CRMR MARHEA, Institut Imagine, Necker-Enfants Malades Hospital, APHP, Paris Cité University, Paris, France, <sup>3</sup>Department of Nephrology, Necker-Enfants Malades Hospital, APHP, Paris, France, <sup>4</sup>Department of Clinical Microbiology, Necker Enfants-Malades Hospital, AP-HP, Paris Cité University, Paris, France, <sup>5</sup>Pasteur Institut, Paris Cité University, Pathogen Discovery Laboratory, Paris, France and <sup>6</sup>Pasteur Institut, Paris Cité University, The OIE Collaborating Center for the Detection and Identification in Humans of Emerging Animal Pathogens, Paris, France

\*These authors contributed equally to this work.

Correspondence to: Pierre Isnard; E-mail: pierre.isnard@aphp.fr

## ABSTRACT

**Background.** Renal arcuate vein thrombosis (RAVT) is a rare and recently recognized cause of acute kidney injury (AKI) in young adults. However, the precise incidence and underlying pathophysiologic mechanisms leading to AKI in these patients remain elusive.

**Methods.** This study included all patients who underwent a kidney biopsy over a 40-month period sent to the pathology department of Necker-Enfants Malades Hospital, with evidence of RAVT. We performed coagulation tests, genetic testing for thrombophilia, complete urine toxicologic screening and kidney metagenomic sequencing to identify an underlying cause of thrombosis.

**Results.** We report five pediatric cases of RAVT discovered on kidney biopsy performed in the setting of unexplained AKI. Investigations did not reveal an underlying cause of thrombosis but only a significant nonsteroidal anti-inflammatory drugs (NSAIDs) use was reported in 4/5 patients, supporting a potential link between NSAIDs use and RAVT. By performing metagenomic sequencing on kidney biopsy samples, we detected severe acute respiratory syndrome coronavirus 2 (SARS-CoV-2) RNA in the kidney of one patient. These results suggest that systemic SARS-CoV-2 infection may also be a key contributing factor of renal thrombosis, particularly by inducing potential endothelial disruption.

**Conclusions.** In conclusion, RAVT-induced AKI appears to be a multiple hit-mediated disease in which NSAIDs consumption and viral infection such as SARS-CoV-2 may be crucial contributing factors. These findings may have significant public health implications given the prevalence of NSAIDs use in the general population. Increased

Received: 3.8.2022; Editorial decision: 10.10.2022

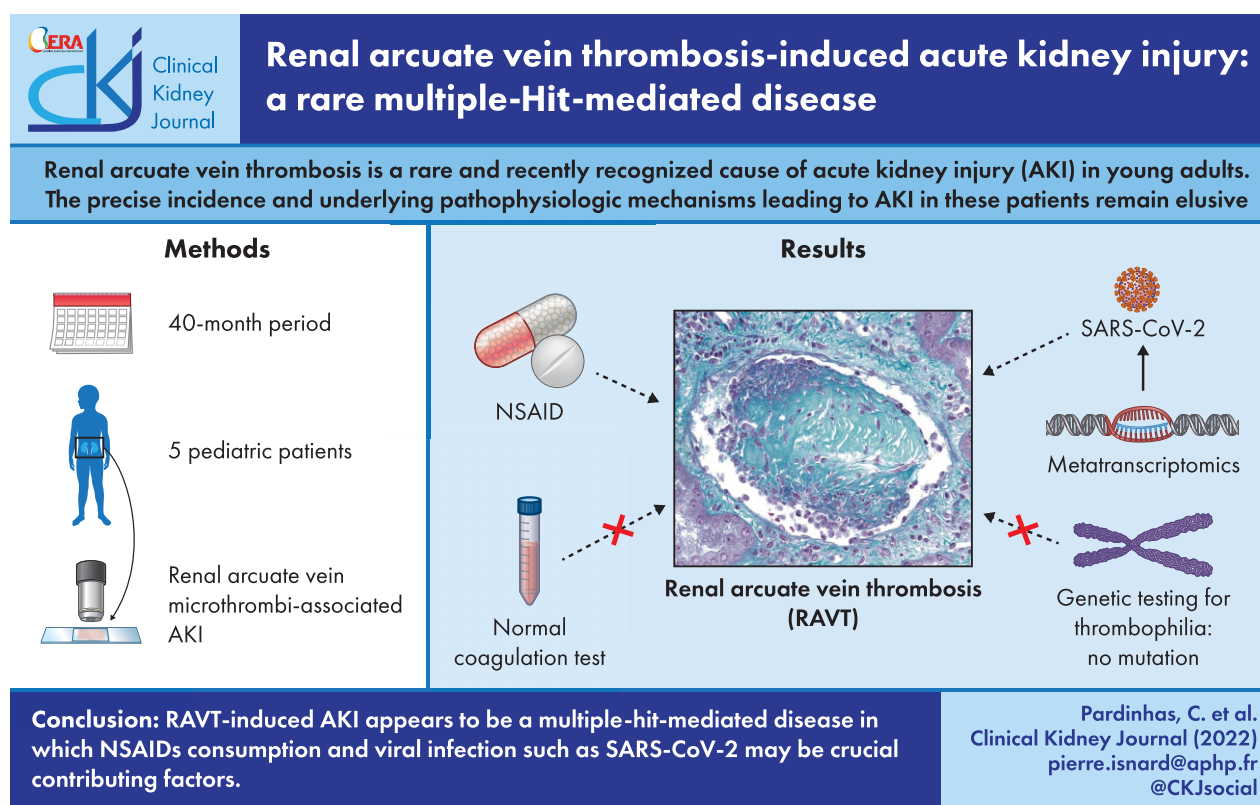
© The Author(s) 2022. Published by Oxford University Press on behalf of the ERA. This is an Open Access article distributed under the terms of the Creative Commons Attribution-NonCommercial License (<https://creativecommons.org/licenses/by-nc/4.0/>), which permits non-commercial re-use, distribution, and reproduction in any medium, provided the original work is properly cited. For commercial re-use, please contact [journals.permissions@oup.com](mailto:journals.permissions@oup.com)

awareness and additional study of future cases may lead to a better understanding of this rare cause of AKI in children and young adults.

## LAY SUMMARY

Renal arcuate vein thrombosis (RAVT) is a recently recognized cause of acute kidney injury (AKI) in young adults. In our study, we reported five pediatric cases of RAVT discovered on kidney biopsy performed in the setting of unexplained AKI. Investigations did not reveal an underlying cause of thrombosis. Nevertheless, a significant NSAIDs use was reported in 4/5 patients supporting a potential link between NSAIDs and RAVT. By performing metagenomic sequencing on kidney biopsy samples, we detected severe acute respiratory syndrome coronavirus 2 (SARS-CoV-2) RNA in one patient, suggesting that systemic SARS-CoV-2 infection may also be a key factor contributing factor to RAVT, particularly by inducing endothelial disruption. RAVT-induced AKI appears to be a multiple hit-mediated disease in which NSAIDs consumption and viral infection such as SARS-CoV-2 may be crucial contributing factors. Increased awareness and additional study of future cases may lead to a better understanding of this rare cause of AKI in children and young adults.

## GRAPHICAL ABSTRACT



**Keywords:** acute kidney injury, metatranscriptomics, NSAIDs, renal arcuate vein thrombosis, SARS-CoV-2

## INTRODUCTION

Acute kidney injury (AKI) is defined as the sudden decline in kidney function as evidenced by a rise in serum creatinine from baseline, and/or a reduction in urine output. Pediatric AKI is an heterogeneous disease with a wide range of clinical severity and multiple causes [1]. The precise incidence of pediatric AKI is hard to determine partly due to the lack of a consensus definition. In a large study of 1.5 million children between 2008 and 2016, community-based pediatric AKI incidence was approximately 1 per 1000 persons [2]. Among the wide range of

intrinsic AKI etiologies, the use of nephrotoxic medications is a common cause of AKI in children. In particular, nonsteroidal anti-inflammatory drugs (NSAIDs) is one of the most frequent contributors to AKI and accounts for 3%–7% of AKI cases in hospitalized children [3]. NSAIDs can induce several forms of kidney failure ranging from hemodynamically mediated AKI without pathological lesions to different types of pathological damage, with acute tubular injury and acute interstitial nephritis being the most common lesions [4].

Renal vein thromboses (RVT) are rare and underdiagnosed entities with the potential to lead to AKI and life-threatening

thromboembolic events [5]. In children, RVT most commonly occurs secondary to nephrotic syndrome and renal transplantation [6, 7]. Nevertheless, as RVT may be promoted by an underlying hypercoagulable state, the systematic search of inherited or acquired procoagulant disorders is required [5]. RVT is often difficult to diagnose as it may remain asymptomatic and be discovered incidentally by imaging studies. However, it should be considered in cases of flank pain and hematuria with or without AKI. It is noteworthy that, although venous thrombosis of the extra renal veins is a well-established cause of AKI, isolated intrarenal venous thrombosis discovered on pathological analysis of renal biopsy is not widely reported as a cause of acute renal failure. Importantly, a recent study by Redfern *et al.* reported thrombosis in the renal arcuate veins (RAVT) demonstrated by kidney biopsy in young adult patients with AKI [8]. However, the precise incidence and underlying pathophysiologic mechanisms of RAVT leading to AKI in these patients remain elusive.

In this study, we report five pediatric cases of RAVT discovered on microscopic analysis of the kidney biopsy performed in the setting of unexplained AKI. We performed complete investigations to identify an underlying cause of thrombosis and determined the relative frequency of these lesions among other causes of AKI in children.

## MATERIALS AND METHODS

### Patients

We performed a single center, retrospective study that included all patients who underwent a kidney biopsy, sent to the pathology department of Necker-Enfants Malades Hospital, over a 40-month period (between 1 January 2019 and 1 May 2022), with evidence of RAVT.

In order to identify underlying promoting factors of venous thrombosis, coagulation test, platelet count, genetic testing for Factor V Leiden and Prothrombin G20210A mutations, test for lupus anticoagulant and anti-cardiolipin antibodies, and complete urine toxicologic screening were performed.

As a comparison, we recorded all pediatric AKI of any cause during the same inclusion period and in particular those attributed to the use of NSAIDs with or without kidney biopsies. Data collection (clinical and biological) was based on patients' medical records.

### Histological analysis

Histopathological examination (optical microscopy) was performed by a kidney pathologist. Briefly, kidney biopsies were fixed in formalin, alcohol and acetic acid, and paraffin embedded. Four- $\mu$ m sections were stained with hematoxylin–eosin, periodic acid–Schiff, Masson trichrome and methenamine silver.

### Immunohistochemistry and immunofluorescence

For immunohistochemical (IHC) analysis, an automated BOND-III (Leica Biosystems) stainer was used. Briefly, 4- $\mu$ m sections of paraffin-embedded kidneys were submitted for appropriate antigen retrieval. Then, sections were incubated with the following antibodies: mouse monoclonal anti-CD34 antibody (Agilent, 1:100) and rabbit polyclonal anti-Factor VIII antibody (Agilent, 1:200).

Immunofluorescence was performed on frozen kidney biopsies with an antibody targeting fibrinogen (rabbit polyclonal

anti-Fibrinogen-FITC, Agilent, F011102) using the automated BOND-III.

### Metatranscriptomics

Molecular analyses were performed on all five kidney biopsies. Nucleic acids from nitrogen-frozen and Optimal Cutting Temperature-embedded kidney biopsies according manufacturer procedure (MagNA Pure Compact RNA Isolation kit, Roche Molecular Systems, Inc.). Metatranscriptomics analyses were performed as previously described [9].

### SARS-CoV-2 RT-PCR assay

Total RNA was extracted from nitrogen-frozen and Optimal Cutting Temperature-embedded kidney biopsies and used to perform real-time polymerase chain reaction (RT-PCR) on nucleocapsid (N) and RNA-dependent RNA polymerase (RdRp) genes according to the manufacturer's instructions (ARGENE SARS-CoV-2 R-GENE, BioMérieux, France).

## RESULTS

Between 1 January 2019 and 1 May 2022, we identified five pediatric cases of RVT in which the diagnosis was made by kidney biopsy performed in the setting of unexplained AKI. The demographic characteristics, clinical and biological data of the patients are provided in Table 1. Briefly, there were one male and four females and patients had a mean age of 15 years (range 13–17 years). No notable comorbidities and no familial history of kidney disorder were reported. Moreover, all five patients had previous normal kidney function. All patients presented to the emergency department with relatively different symptoms; however, three of them presented with abdominal or flank pain. Importantly, biochemical studies revealed AKI with a mean serum creatinine at admission of 285  $\mu$ mol/L (range 209–460  $\mu$ mol/L). No relevant proteinuria was detected except for Patient 4 (300 mg/mmol of urine creatinine without nephrotic syndrome) and two patients presented with mild hematuria. There were no relevant findings in the renal ultrasound performed, in particular no thrombus forms in the renal veins or their branches were observed on the Doppler sonography. Of particular interest, in four patients, there was a significant consumption (one to three doses) of NSAIDs previous to the episode without other nephrotoxic medications. Nevertheless, Patient 2 reported taking only paracetamol in the 2 days before due to arthralgia and flu-like symptoms. Importantly, Patient 3 with past history of depression reported voluntary poisoning with a high dose of ketoprofen (14 tablets).

All patients had negative severe acute respiratory syndrome coronavirus 2 (SARS-CoV-2) nasopharyngeal swab tests upon admission and SARS-CoV-2 serological testing was negative in two patients, whereas three patients had positive SARS-CoV-2 anti-S antibodies. The coagulation test, genetic test and toxicologic investigations are provided in Table 1. For all patients, platelet count and coagulation tests were within normal range. Genetic testing was negative for Factor V Leiden and Prothrombin G20210A mutations for all patients, arguing against a potential inherited thrombophilia. Moreover, lupus anticoagulant and anti-cardiolipin antibodies were negative in the three tested patients. All urine samples were sent for complete toxicology screening which did not detect alcohols and recreational drugs.

A kidney biopsy was performed on all patients in the etiological work-up of AKI. All biopsy specimens had material taken

Table 1: Summary of clinical and biological characteristics.

Patient	Sex	Age (years)	Clinical presentation	Admission creatinine (μmol/L)	Urine dipstick	Pu (mg/mmol)	Ultrasound findings	Medications before admission	Platelet count (/mm <sup>3</sup> )	Coagulation test	Genetic test	Urine toxicology	Microbiology (NGS)
1	F	17	Asthenia Flank pain	205	No hematuria No proteinuria	57	Normal	NSAIDs	201 000	Normal range	No mutation	Negative	No pathogen
2	F	15	Asthenia Arthralgia Polydipsia and polyuria	209	Hematuria Proteinuria	106.8	Normal	Paracetamol	249 000	Normal range	No mutation	Negative	No pathogen
3	F	13	Voluntary poisoning	230	Hematuria Proteinuria	30	Normal	NSAIDs	459 000	Normal range	No mutation	Negative	No pathogen
4	M	15	Abdominal pain Vomiting	322	No hematuria Proteinuria	300	Normal	NSAIDs	242 000	Normal range	No mutation	NA	No pathogen
5	F	13	Abdominal pain Vomiting	460	No hematuria No proteinuria	30	Normal	NSAIDs	280 000	Normal range	No mutation	Negative	SARS-CoV-2

Coagulation test: prothrombin time, partial thromboplastin time, fibrinogen level, antithrombin activity, protein C level and protein S level.

Genetic test: Prothrombin G20210A and Factor V Leiden.

Urine toxicology: ethanol, benzodiazepine, amphetamine, methamphetamine, cannabis, cocaine, morphine, buprenorphine, methadone, opioid and gamma-hydroxybutyrate.

for light microscopy and immunofluorescence (IF). The light microscopy sample contained cortex and medulla in all cases with 16–31 glomeruli in the cortical area. In each case, histological findings on biopsy were similar. No evidence of acute interstitial nephritis or diffuse acute tubular injury was found (Fig. 1A). However, we observed focal areas of mild tubular injury, little interstitial edema and focal immune cell infiltrate (<10%) concentrated at the corticomedullary junction (Fig. 1B). Of particular interest, morphological analysis revealed in all patients well-defined thrombi in the renal arcuate veins (Fig. 1D), except for Patient 4 where thrombosis was detected on the IF fragment by identification of an intravascular fibrin-positive thrombus (Fig. 1G). IHC analysis using anti-CD34 antibody further demonstrated that the thrombotic lesions were within arcuate veins with focal adhesions of the thrombus to the vessel wall (Fig. 1E). Moreover, IHC analysis using anti-Factor VIII antibody showed platelets aggregates within the thrombus (Fig. 1F). Interestingly, IHC targeting CD34 also showed dilated peritubular capillaries at the corticomedullary junction close to the renal vein, favoring indirect evidence of downstream venous obstruction (Fig. 1C). Of note, IF analysis did not reveal any immunoglobulin or complement fraction deposits in the glomeruli. In total, only the thrombotic lesion of the renal arcuate veins could potentially explain AKI in all patients.

As systemic or localized infections are independent risk factors for thromboembolic diseases, to determine whether this observed renal thrombosis could be directly related to a specific pathogen, we performed metagenomic next-generation sequencing (mNGS) on kidney biopsy samples from all five patients. Four kidney biopsies showed no pathogen sequences and strikingly in Patient 5, SARS-CoV-2 RNA was detected in the kidney and further confirmed by RT-PCR.

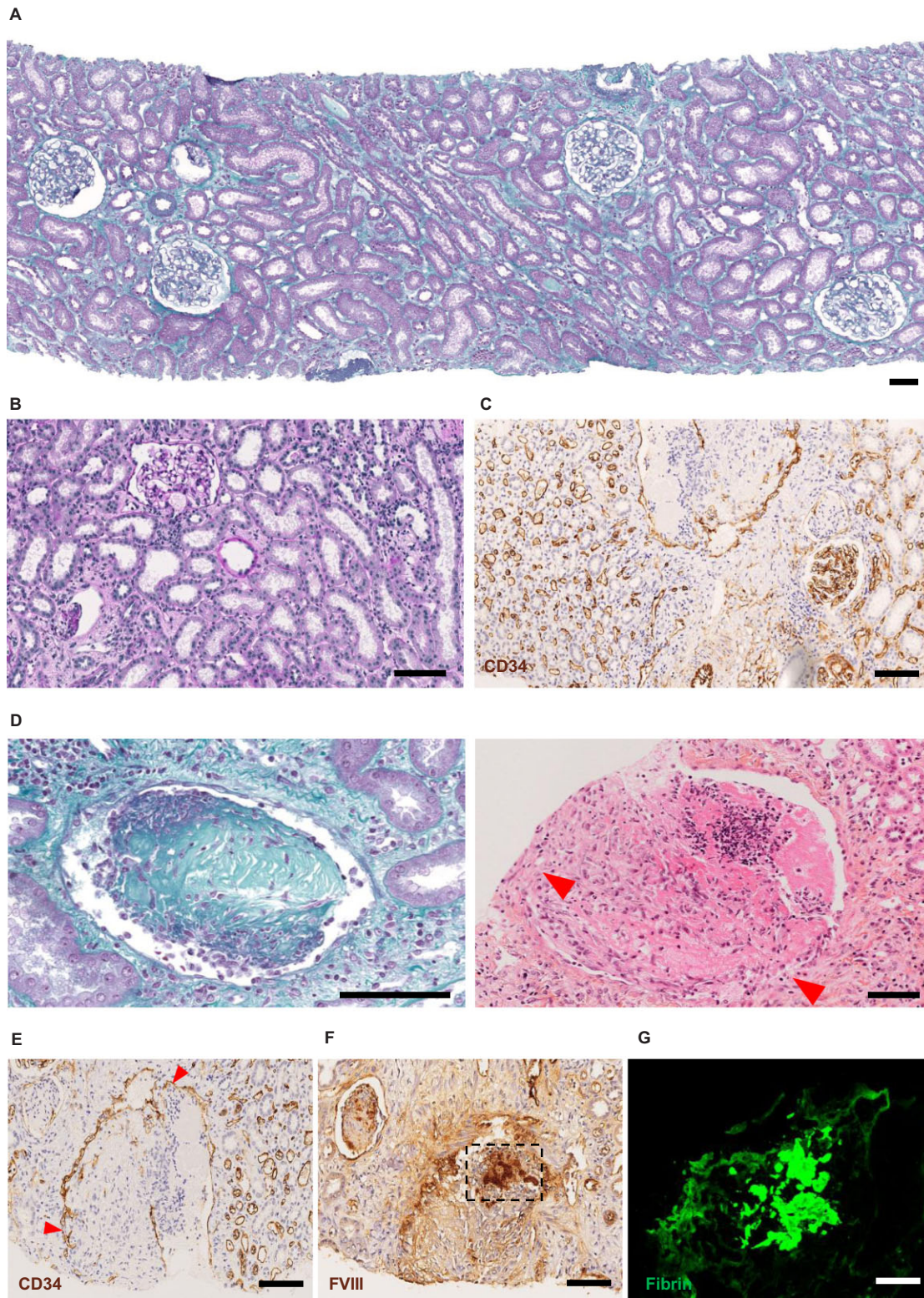
NSAID treatment was discontinued and all five patients showed an improvement in renal function with only supportive measures within 15 days.

In order to establish the frequency of this atypical cause of AKI potentially related to NSAIDs use, we identified over the same inclusion period all pediatric AKI, regardless of the cause, with or without renal biopsies performed at the time of diagnosis. We therefore identified in this 3 years and 5 months period 79 pediatric patients admitted to our nephrology department for AKI. Among them, 16 (20.3%) were attributed to NSAIDs use and 7 had a kidney biopsy, with 5 (6.3% of AKI patients) corresponding to the reported series and 2 with acute tubular injuries lesions. In total, the precise incidence of our observed NSAIDs-associated renal arcuate vein thrombosis is difficult to determine because of the potential large number of undiagnosed cases related to the restricted indication of kidney biopsy in these contexts. However, among the 16 patients with NSAIDs-associated AKI, a high proportion ( $n = 5$ , 31%) had an RAVT. As arcuate blood vessels may not be invariably present in a renal biopsy and may result in a bias for underestimation, we randomly analyzed 182 pediatric kidney biopsies during a 1-year period to estimate an overall percentage of the occurrence of these vessels in kidney biopsies. We identified 118 (64.8%) renal biopsies with arcuate blood vessels at the corticomedullary junction suggesting that in one out of three cases the diagnosis may be missed due to sampling bias.

## DISCUSSION

Pediatric AKI is a heterogenous disease with a wide range of causes [1]. NSAIDs medications is one of the most frequent contributors to pediatric AKI accounting for 3%–7% of AKI cases





**Figure 1:** Microscopy analysis of kidney biopsies. (A) Representative image of patient's kidney biopsies using light microscopy with Masson's trichrome staining, showing mostly normal kidney parenchyma. (B) Light microscopy using periodic acid-Schiff staining showing focal mild tubular injury with interstitial edema and focal immune cells infiltrate. (C) IHC analysis on kidney biopsy targeting CD34 showing dilated peritubular capillaries at the corticomedullary junction close to the RAVT. (D) Light microscopy using Masson's trichrome (left) and hematoxylin-eosin (right) staining, showing two dilated renal arcuate veins at the corticomedullary junction containing a large thrombus composed mainly of fibrin with inflammatory cells. Red arrows show focal adhesions of the thrombus to the vessel wall. (E) IHC analysis on renal arcuate vein thrombosis targeting CD34 showing the thrombus within an arcuate vein with strong staining of the endothelium. Red arrows show focal adhesions of the thrombus to the vessel wall. (F) IHC analysis on RAVT targeting Factor VIII showing platelets aggregates within the thrombus. (G) IF analysis on RAVT targeting fibrinogen showing a thrombus composed mainly of fibrin. Scale bar 100 µm.



in hospitalized children [3]. Of note, when a kidney biopsy is performed acute tubular injury and acute interstitial nephritis are the most common pathological lesions observed in NSAIDs-induced AKI. Conversely, RVT is not a common cause of pediatric AKI and most commonly occurs secondary to nephrotic syndrome and renal transplantation [6, 7]. In contrast, malignancy and nephrotic syndrome are the most common underlying causes of RVT in adult patients [10].

Intrarenal venous thrombosis solely discovered on pathological analysis of renal biopsy is not widely reported as a cause of AKI. An interesting study by Redfern et al. recently reported six young adults with AKI and thrombosis in the renal arcuate veins demonstrated by kidney biopsy [8]. However, in this study, the specific causality and the underlying pathophysiologic mechanisms remained elusive. Strikingly, as in our report, affected patients were all healthy young adults and teenagers with renal arcuate vein thrombosis revealed on microscopic analysis of the kidney biopsy performed in the setting of unexplained AKI. Moreover, as we reported, all patients achieved a complete recovery of renal function in about 2 weeks. The main difference of our study is that most of our patients (4/5 patients) had consumed a moderate to high dose of NSAIDs in the days before presentation, allowing proposal of a possible causal link between NSAIDs used and RAVT. Of interest, in the Redfern et al. study, NSAIDs consumption before admission was also identified in 3/6 patients. Among other potential causes of RAVT, recreational drug use and alcohol have been considered as potential etiologic factors. However, in our study, no evidence of recreational drug use or alcohol consumption were identified in the four patients who underwent extensive urine toxicology screening.

In cases of rapid onset and complete occlusion of the renal vein the affected kidney becomes enlarged due to venous stasis and interstitial edema [5]. Strikingly, in our patients kidney size remained normal as in the six cases reported by Redfern et al. [8]. In contrast to an often unilateral thrombosis of the extra-renal veins, occlusions of the arcuate veins certainly affect both kidneys, given the level of renal insufficiency observed, but probably do not involve the entire network of arcuate veins, with therefore the possibility of accessory lymphatic or venous drainage limiting edema and renal volume gain.

Virchow's triad comprises three factors predisposing to thrombus formation: abnormal blood flow, hypercoagulability and endothelial injury. Of particular interest, NSAIDs, by affecting intrarenal hemodynamics, may have been a contributory factor to RAVT in our patients. NSAIDs promote renal vasoconstriction by reducing prostaglandin production and blunting their vasodilatation effect on the afferent arteriole leading to dominant vasoconstriction and reduced glomerular filtration rate [4]. Of note, two patients also presented with vomiting that may have contributed to intrarenal hemoconcentration, favoring a thrombotic event. In addition, several studies suggest an increased risk of venous thromboembolism among NSAID users, further emphasizing the potential link between NSAIDs and RAVT [11, 12]. It is worth noting that no other cause of thrombosis-promoting factors has been identified in our patients, such as thrombophilia.

Also, in relation to Virchow's triad, systemic or localized infections are independent risk factors for venous thrombosis, especially by promoting endothelial disruption and platelet activation [13]. In this respect, we performed mNGS on all kidney biopsy samples and strikingly we detected SARS-CoV-2 RNA in the kidney biopsy of Patient 5. Of interest, in the coronavirus disease 2019 (COVID-19) pandemic several studies have underlined the increased risk of thromboembolic diseases and identified the

crucial role of endothelial cells in the genesis of these thromboembolic events [14, 15]. Indeed, SARS-CoV-2 is likely to cause endothelial disruption and thrombosis through direct entry into endothelial cells and induction of pro-inflammatory cytokines [15–17]. Thus, in our patient viral-induced endothelial activation might have been a crucial promoting factor of RAVT.

In conclusion, RAVT is a rare but probably underdiagnosed cause of AKI in children and young adults. RAVT appears to be a multiple hit-mediated disease in which NSAIDs consumption and viral infection such as SARS-CoV-2 may be crucial contributing factors. Importantly, our findings may have significant public health implications given the prevalence of NSAIDs use in the general population. Increased awareness and additional study of future cases may lead to a greater understanding of this rare cause of AKI in children and young adults.

## DATA AVAILABILITY STATEMENT

All data are incorporated into the article without online supplementary material.

## CONFLICT OF INTEREST STATEMENT

Authors have disclosed no conflicts of interest.

## REFERENCES

- Devarajan P. The current state of the art in acute kidney injury. *Front Pediatr* 2020;8:1–8. <http://dx.doi.org/10.3389/fped.2020.00070>.
- Parikh RV, Tan TC, Salyer AS et al. Community-based epidemiology of hospitalized acute kidney injury. *Pediatrics* 2020;146:e20192821.
- Misurac JM, Knoderer CA, Leiser JD et al. Nonsteroidal anti-inflammatory drugs are an important cause of acute kidney injury in children. *J Pediatr* 2013;162:1153–9.e1. <http://dx.doi.org/10.1016/j.jpeds.2012.11.069>.
- Lucas GNC, Leitão ACC, Alencar RL et al. Pathophysiological aspects of nephropathy caused by non-steroidal anti-inflammatory drugs. *Braz J Nephrol* 2019;41:124–30. <http://dx.doi.org/10.1590/2175-8239-jbn-2018-0107>.
- Asghar M, Ahmed K, Shah SS et al. Renal vein thrombosis. *Eur J Vasc Endovasc Surg* 2007;34:217–23. <http://dx.doi.org/10.1016/j.ejvs.2007.02.017>.
- Tinaztepe K, Buyan N, Tinaztepe B et al. The association of nephrotic syndrome and renal vein thrombosis: a clinicopathological analysis of eight pediatric patients. *Turk J Pediatr* 1989;31:1–18. <https://europepmc.org/article/med/2609431>.
- Harmon WE, Stablein D, Alexander SR et al. Graft thrombosis in pediatric renal transplant recipients: a report of the north American pediatric renal transplant cooperative study. *Transplantation* 1991;51:406–12. <https://pubmed.ncbi.nlm.nih.gov/1994535/>. <http://dx.doi.org/10.1097/00007890-199102000-00026>.
- Redfern A, Mahmoud H, McCulloch T. et al. Renal arcuate vein microthrombi-associated AKI. *Clin J Am Soc Nephrol* 2015;10:180–6. <http://dx.doi.org/10.2215/CJN.01540214>.
- Pérot P, Bielle F, Bigot T. et al. Identification of umbre orthobunyavirus as a novel zoonotic virus responsible for lethal encephalitis in 2 French patients with hypogammaglobulinemia. *Clin Infect Dis* 2021;72:1701–8. <http://dx.doi.org/10.1093/cid/ciaa308>.

10. Wysokinski WE, Gosk-Bierska I, Greene EL et al. Clinical characteristics and long-term follow-up of patients with renal vein thrombosis. *Am J Kidney Dis* 2008;**51**:224–32. <http://dx.doi.org/10.1053/j.ajkd.2007.10.030>.
11. Schmidt M, Christiansen CF, Horváth-Puhó E et al. Non-steroidal anti-inflammatory drug use and risk of venous thromboembolism. *J Thromb Haemost* 2011;**9**:1326–33. <http://dx.doi.org/10.1111/j.1538-7836.2011.04354.x>.
12. Ungprasert P, Srivali N, Wijarnpreecha K et al. Non-steroidal anti-inflammatory drugs and risk of venous thromboembolism: a systematic review and meta-analysis. *Rheumatology (Oxford)* 2015;**54**:736–42. <http://dx.doi.org/10.1093/rheumatology/keu408>.
13. Beristain-Covarrubias N, Perez-Toledo M, Thomas MR et al. Understanding infection-induced thrombosis: lessons learned from animal models. *Front Immunol* 2019;**10**:2569. <http://dx.doi.org/10.3389/fimmu.2019.02569>.
14. Helms J, Tacquard C, Severac F et al. High risk of thrombosis in patients with severe SARS-CoV-2 infection: a multicenter prospective cohort study. *Intensive Care Med* 2020;**46**:1089–98. <https://doi.org/10.1007/s00134-020-06062-x>. <http://dx.doi.org/10.1007/s00134-020-06062-x>.
15. Pons S, Fodil S, Azoulay E et al. The vascular endothelium: the cornerstone of organ dysfunction in severe SARS-CoV-2 infection. *Critical Care* 2020;**24**:4–11. <http://dx.doi.org/10.1186/s13054-020-03062-7>.
16. Aid M, Busman-Sahay K, Vidal SJ et al. Vascular disease and thrombosis in SARS-CoV-2-infected rhesus macaques. *Cell* 2020;**183**:1354–66.e13. <https://doi.org/10.1016/j.cell.2020.10.005>. <http://dx.doi.org/10.1016/j.cell.2020.10.005>.
17. Varga Z, Flammer AJ, Steiger P et al. Endothelial cell infection and endotheliitis in COVID-19. *Lancet* 2020;**395**:1417–8. [http://dx.doi.org/10.1016/S0140-6736\(20\)30937-5](http://dx.doi.org/10.1016/S0140-6736(20)30937-5).