

## Disseminated *Spiroplasma apis* Infection in Patient with Agammaglobulinemia, France

Nicolas Etienne, Laurent Bret, Cécile Le Brun, Hervé Lécuyer, Josquin Moraly, Fanny Lanternier, Olivier Hermine, Agnès Ferroni, Marc Lecuit, Sabine Pereyre, et al.

► **To cite this version:**

Nicolas Etienne, Laurent Bret, Cécile Le Brun, Hervé Lécuyer, Josquin Moraly, et al.. Disseminated *Spiroplasma apis* Infection in Patient with Agammaglobulinemia, France. *Emerging Infectious Diseases*, Centers for Disease Control and Prevention, 2018, 24 (12), pp.2382-2386. 10.3201/eid2412.180567 . pasteur-02139189

**HAL Id: pasteur-02139189**

**<https://hal-pasteur.archives-ouvertes.fr/pasteur-02139189>**

Submitted on 24 May 2019

**HAL** is a multi-disciplinary open access archive for the deposit and dissemination of scientific research documents, whether they are published or not. The documents may come from teaching and research institutions in France or abroad, or from public or private research centers.

L'archive ouverte pluridisciplinaire **HAL**, est destinée au dépôt et à la diffusion de documents scientifiques de niveau recherche, publiés ou non, émanant des établissements d'enseignement et de recherche français ou étrangers, des laboratoires publics ou privés.



and serology testing for 12 pathogens. Results from viral cultures on a BAL sample, taken 8 days after hospital admission, showed a cytopathogenic effect on 3 available cell lines (Vero, HEp-2, and MRC5) 7 days after incubation. Results from a PCR, administered in an effort to identify the positive viral culture, for herpes simplex virus and enterovirus were both negative.

Because the general condition of the patient had improved and stabilized, he was weaned from intubation 14 days after admission to the intensive care unit. He was discharged to the geriatric department and slowly recovered consciousness; his neurologic status also normalized. Three months after onset of the infection, the patient described having some memory loss and no memory at all of the days when the infection first started.

Because routine testing did not lead to a diagnosis, a BAL sample and a viral culture were sent to the University Hospital Leuven (Leuven, Belgium). The cell culture was subjected to next-generation sequencing (NGS) with the Novel enrichment technique of VIRomes protocol (5). This protocol includes purification of viral particles, nucleic acid extraction, and random PCR amplification, followed by library preparation and sequencing using Next-Seq 500 system NGS technology (Illumina, San Diego, CA, USA) (6). The sequence reads obtained were filtered and trimmed, de novo assembled, and taxonomically classified (7,8). Analysis of the NGS results identified a complete West Nile virus genome (11,060 nt). To confirm this result, a novel RNA extraction and a reverse transcription PCR (QIAGEN, Venlo, the Netherlands) with newly developed primers were performed on the BAL sample and cell culture, followed by Sanger sequencing (9). The sequence obtained from the positive sample was identical to the sequence from the complete genome obtained by NGS.

The WNV lineage 2 strain in this study, WNV-2|Belgium|2017|Antwerp (GenBank accession number: MH021189), is closely related (99.4%–99.6% nucleotide similarity) to a strain from Hungary and other Balkan countries identified between 2010 and 2015 (Figure), reinforcing the conclusion that this WNV infection was acquired in Hungary. This case illustrates that the combined use of cell cultures and NGS can be a powerful tool for identifying unknown pathogens in clinical specimens when results from routine tests are negative and the patient's condition is undiagnosed.

#### About the Author

Elke Wollants currently works as laboratory manager in the Clinical Virology Lab at the Rega Institute, KU Leuven. Her research interests are identifying pathogens not detected in routine diagnostic laboratory tests and next-generation sequencing.

#### References

- Rizzoli A, Jimenez-Clavero MA, Barzon L, Cordioli P, Figuerola J, Koraka P, et al. The challenge of West Nile virus in Europe: knowledge gaps and research priorities. *Euro Surv.* 2015;20(20).
- Petersen LR, Brault AC, Nasci RS. West Nile virus: review of the literature. *JAMA.* 2013;310:308–15. <http://dx.doi.org/10.1001/jama.2013.8042>
- Cnops L, Papa A, Lagra F, Weyers P, Meersman K, Patsourous N, et al. West Nile virus infection in Belgian traveler returning from Greece. *Emerg Infect Dis.* 2013;19:684–5. <http://dx.doi.org/10.3201/eid1904.121594>
- Van Den Bossche D, Cnops L, Meersman K, Domingo C, Van Gompel A, Van Esbroeck M. Chikungunya virus and West Nile virus infections imported into Belgium, 2007–2012. *Epidemiol Infect.* 2015;143:2227–36. <http://dx.doi.org/10.1017/S0950268814000685>
- Conceição-Neto N, Zeller M, Lefèvre H, De Bruyn P, Beller L, Deboutte W, et al. Modular approach to customise sample preparation procedures for viral metagenomics: a reproducible protocol for virome analysis. *Sci Rep.* 2015;5:16532. <http://dx.doi.org/10.1038/srep16532>
- Conceição-Neto N, Zeller M, Lefèvre H, De Bruyn P, Beller L, Deboutte W, et al. NetoVIR: a reproducible protocol for virome analysis. London: Nature Publishing Group; 2016.
- Bankevich A, Nurk S, Antipov D, Gurevich AA, Dvorkin M, Kulikov AS, et al. SPAdes: a new genome assembly algorithm and its applications to single-cell sequencing. *J Comput Biol.* 2012;19:455–77.
- Buchfink B, Xie C, Huson DH. Fast and sensitive protein alignment using DIAMOND. *Nat Methods.* 2015;12:59–60. <http://dx.doi.org/10.1038/nmeth.3176>
- Wollants E, De Coster S, Van Ranst M, Maes P. A decade of norovirus genetic diversity in Belgium. *Infect Genet Evol.* 2015;30:37–44.

Address for correspondence: Elke Wollants, Rega Institute, KU Leuven, Laboratory of Clinical Virology, Herestraat 49 box 1040 Leuven 3000, Belgium; email: [elke.wollants@kuleuven.be](mailto:elke.wollants@kuleuven.be)

## Disseminated *Spiroplasma apis* Infection in Patient with Agammaglobulinemia, France

Nicolas Etienne, Laurent Bret,  
Cécile Le Brun, Hervé Lecuyer, Josquin Moraly,  
Fanny Lanternier, Olivier Hermine,  
Agnès Ferroni, Marc Lecuit, Sabine Pereyre,<sup>1</sup>  
Laure Beven,<sup>1</sup> Olivier Lortholary<sup>1</sup>

Author affiliations: Paris Descartes University Hospital, Paris, France (N. Etienne, H. Lecuyer, F. Lanternier, O. Hermine, A. Ferroni, M. Lecuit, O. Lortholary); Centre Hospitalier Régional,

Orléans, France (L. Bret); Centre Hospitalier Régional Universitaire, Tours, France (C. Le Brun); Pasteur Institute, Paris (M. Lecuit); University of Bordeaux, Bordeaux, France (S. Pereyre); University of Bordeaux, Villenave d'Ornon, France (L. Beven)

DOI: <https://doi.org/10.3201/eid2412.180567>

We report a disseminated infection caused by *Spiroplasma apis*, a honeybee pathogen, in a patient in France who had X-linked agammaglobulinemia. Identification was challenging because initial bacterial cultures and direct examination by Gram staining were negative. Unexplained sepsis in patients with agammaglobulinemia warrants specific investigation to identify fastidious bacteria such as *Spiroplasma* spp.

In February 2017, a 40-year-old man in France who was under immunoglobulin replacement therapy for X-linked agammaglobulinemia experienced a migrating nonitchy papular eruption. Skin biopsy revealed nonspecific lymphocytic dermatitis. One month later, he experienced distal interphalangeal arthritis. Histology of a synovial biopsy sample found a nonspecific lymphocytic infiltrate. Bacterial cultures were negative. In April 2017, febrile arthritis of the left ankle and right knee appeared, along with bilateral wrist and finger tenosynovitis (online Technical Appendix, <https://wwwnc.cdc.gov/EID/article/24/12/18-0567-Techapp1.pdf>). We initiated ceftriaxone (1 g/d) and performed a left ankle joint aspiration 24 hours later. The patient remained febrile with a pulmonary valve murmur of tricuspid regurgitation and purpuric lesions, tenosynovitis in the left ankle and both wrists, and right knee and interphalangeal polyarthritis. Serum C-reactive protein was 136 mg/dL and IgG serum level 9.4 g/L. Transesophageal echography showed slight tricuspid regurgitation. Arthritis worsened, and we performed a right knee joint aspiration. Four of 6 blood cultures were positive after 55 h of incubation at 37°C (Bactec FX; Becton Dickinson, Franklin Lakes, NJ, USA). Results of direct examination by Gram staining of positive blood cultures and real-time multiplex PCR for blood culture identification (FilmArray BCID Panel; bioMérieux, Marcy l'Etoile, France) were negative. Small  $\alpha$ -hemolytic areas appeared on subcultures in horse blood agar after 5 days of aerobic culture; results of mass spectrometry performed on these areas were negative. Blood culture-specific PCR targeting *Tropheryma whippelii*, *Bartonella* spp., *Brucella* spp., *Coxiella burnetii*, and *Rickettsia* spp. showed negative results.

At this stage, we modified antimicrobial therapy to be optimal for *Mycoplasma*, *Chlamydia*, deficient streptococci, *Campylobacter*, and *Helicobacter* regarding the context of agammaglobulinemia. We introduced amoxicillin/clavulanic acid (12 g/1,200 mg/d) associated with levofloxacin (500 mg 2×/d), leading to apyrexia and negative blood culture after 1 day. Results of testing for *Chlamydia trachomatis* (by PCR

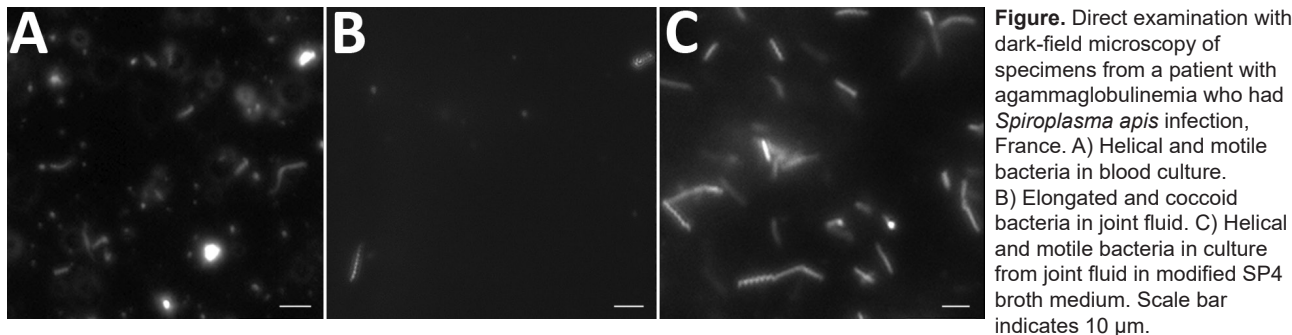
and culture) and *Ureaplasma* spp. and *Mycoplasma hominis* (by culture) in urine were negative. We seeded synovial fluid on blood culture, and small colonies developed on horse blood agar. We extracted DNA from the zone of hemolysis using EZ1 DNA tissue kit (QIAGEN, Valencia, CA, USA). We amplified and sequenced the 16S rRNA gene with the primer set 27F/16S1RRB as previously described (1) and performed bacterial identification using phylogenetic analysis on the Bioinformatics Bacterial Identification tool (2). The 491-bp amplicon sequence was 100% identical to that of *Spiroplasma apis* strain ATCC 33834 (GenBank accession no. GU993267). We confirmed identification of *S. apis* by specific *S. apis* PCR (3) and culture (on modified SP4 agar) in synovial fluid from left ankle and right knee and in blood culture. Direct examination of synovial fluid and blood culture with dark field microscopy allowed identification of bacteria with a helical morphology and motility evocative of spiroplasmas (Figure). We obtained highly enriched *Spiroplasma* cultures starting from fluid and blood cultures. We retrospectively found specific PCR for *S. apis* positive in synovial biopsy from the distal interphalangeal sample. Antimicrobial drug susceptibility testing showed susceptibility to macrolides, tetracyclines, and fluoroquinolones and resistance to rifampin, cotrimoxazole, and penicillin G. Tetracycline and fluoroquinolone MIC values were similar to those reported for *Ureaplasma* spp.

Patient's condition gradually improved with 6-week administration of levofloxacin and iterative joint aspirations of the right knee. Because of severe tendinopathy, levofloxacin was stopped after 6 weeks and replaced by azithromycin (500 mg/d) and doxycycline (200 mg 2×/d) for 6 weeks.

Patients with agammaglobulinemia are susceptible to infections, including mycoplasma infections (4). Invasive infections such as endocarditis and septic arthritis have been reported with *M. hominis* and *Ureaplasma urealyticum* in hypogammaglobulinemic patients. Of note, our patient contracted mycoplasma infection despite an appropriate gammaglobulin serum level (IgG 9.4 g/L).

Spiroplasmas, arthropod-infecting bacteria of the class Mollicutes, are similar to mycoplasmas. Pathogenic species include *S. apis*, detected in hives in southwestern France (5). *S. apis* is associated with the lethal May disease of the European honeybee *Apis mellifera*. Its prevalence in bee colonies in France was not reported but was recently shown to reach high percentages in other countries (6). Only 3 cases of human infection due to *Spiroplasma* spp. have been reported: hepatitis in a lung transplant recipient (7), uveitis in a premature neonate (8), and bacteremia in a patient under certolizumab treatment (9). None of these infections correlated with any noticeable insect bite history. In contrast, the patient we report had multiple stings by a flying insect resembling a hornet in August 2016, in the Loiret department of France, leading to cutaneous blebs and transitory rash. This finding raises the possibility that *S. apis* might infect insects other

<sup>1</sup>These authors contributed equally to this article.



**Figure.** Direct examination with dark-field microscopy of specimens from a patient with agammaglobulinemia who had *Spiroplasma apis* infection, France. A) Helical and motile bacteria in blood culture. B) Elongated and coccoid bacteria in joint fluid. C) Helical and motile bacteria in culture from joint fluid in modified SP4 broth medium. Scale bar indicates 10 µm.

than honeybees. The insect stings in this patient are a likely gateway of the reported infection.

In summary, clinicians and microbiologists should be aware of fastidious organisms in atypical infections in immunocompromised patients. Our findings indicate a need for prolonged culture on specific agar on all joint fluids in patients with agammaglobulinemia and targeted molecular methods to identify *S. apis* organisms.

#### Acknowledgments

We thank Anne Laurence Thomi Georgelin, who referred the patient to the Necker-Pasteur Center for Infectious Diseases and Tropical Medicine; Valérie Zeller for the management of septic polyarthrititis; and Philippe Lanotte and Marie-Pierre Dubrana, who participated in molecular analysis.

#### About the Author

Dr. Etienne is an infectious disease clinician and a clinical immunologist in Necker-Pasteur Center for Infectious Diseases, Paris. His research interest focuses on infections in immunocompromised patients.

#### References

1. Schabereiter-Gurtner C, Nehr M, Apfalter P, Makristathis A, Rotter ML, Hirschl AM. Evaluation of a protocol for molecular broad-range diagnosis of culture-negative bacterial infections in clinical routine diagnosis. *J Appl Microbiol.* 2008;104:1228–37. <http://dx.doi.org/10.1111/j.1365-2672.2007.03648.x>
2. Devulder G, Perrière G, Baty F, Flandrois JP. BIBI, a bioinformatics bacterial identification tool. *J Clin Microbiol.* 2003; 41:1785–7. <http://dx.doi.org/10.1128/JCM.41.4.1785-1787.2003>
3. Meeus I, Vercruyse V, Smaghe G. Molecular detection of *Spiroplasma apis* and *Spiroplasma melliferum* in bees. *J Invertebr Pathol.* 2012;109:172–4. <http://dx.doi.org/10.1016/j.jip.2011.11.006>
4. Blanchard A, Bébéar CM. Mycoplasmas of humans. In: Razin S, Herrmann R, editors. *Molecular biology and pathogenicity of mycoplasmas.* New York: Kluwer Academic/Plenum Publishers; 2002. p. 45–71.
5. Mouches C, Bové JM, Tully JG, Rose DL, McCoy RE, Carle-Junca P, et al. *Spiroplasma apis*, a new species from the honey-bee *Apis mellifera*. *Ann Microbiol (Paris).* 1983;134A:383–97.
6. Schwarz RS, Teixeira ÉW, Tauber JP, Birke JM, Martins MF, Fonseca I, et al. Honey bee colonies act as reservoirs for two *Spiroplasma* facultative symbionts and incur complex, multiyear infection dynamics. *MicrobiologyOpen.* 2014;3:341–55. <http://dx.doi.org/10.1002/mbo3.172>

7. Mueller NJ, Tini GM, Weber A, Gaspert A, Husmann L, Bloemberg G, et al. Hepatitis from *Spiroplasma* sp. in an immunocompromised patient. *Am J Transplant.* 2015;15:2511–6. <http://dx.doi.org/10.1111/ajt.13254>
8. Lorenz B, Schroeder J, Reischl U. First evidence of an endogenous *Spiroplasma* sp. infection in humans manifesting as unilateral cataract associated with anterior uveitis in a premature baby. *Graefes Arch Clin Exp Ophthalmol.* 2002;240:348–53. <http://dx.doi.org/10.1007/s00417-002-0453-3>
9. Aquilino A, Masiá M, López P, Galiana AJ, Tovar J, Andrés M, et al. First human systemic infection caused by *Spiroplasma*. *J Clin Microbiol.* 2015;53:719–21. <http://dx.doi.org/10.1128/JCM.02841-14>

Address for correspondence: Olivier Lortholary, Necker-Enfants Malades University Hospital, 149 rue de Sevres 75743, Paris CEDEX, France; email: [olivier.lortholary@aphp.fr](mailto:olivier.lortholary@aphp.fr)

## ***Mycoplasma ovipneumoniae* in Wildlife Species beyond Subfamily Caprinae**

**Margaret A. Highland, David R. Herndon, Scott C. Bender, Lisa Hansen, Robert F. Gerlach, Kimberlee B. Beckmen**

Author affiliations: Washington Animal Disease Diagnostic Laboratory, Pullman, Washington, USA (M.A. Highland); US Department of Agriculture, Pullman (M.A. Highland, D.R. Herndon); Navajo Technical University, Crownpoint, New Mexico, USA (S.C. Bender); Barron Veterinary Clinic, Barron, Wisconsin, USA (L. Hansen); Alaska Department of Environmental Conservation, Anchorage, Alaska, USA (R.F. Gerlach); Alaska Department of Fish and Game, Fairbanks, Alaska (K.B. Beckmen)

DOI: <https://doi.org/10.3201/eid2412.180632>